

## W O N D E R   W H Y ?

# The Use of Testosterone and Growth Hormone for Prolotherapy

Thomas Ravin, MD

## ABSTRACT

*Most physicians practicing musculoskeletal medicine appreciate the importance of testosterone and growth hormone in health and wellness. The significance of these hormones in the earliest phases of wound healing and tissue repair recently has been elucidated. Testosterone and growth hormone play key roles in regulating cell functions, from stimulating protein production (a slow process called genomic effects) to altering cell functions in time periods ranging from a second or two to a couple of minutes (called non-genomic effects). The non-genomic effects play a role in Prolotherapy treatments by releasing signaling molecules, altering cell wall flexibility, modifying pain perception, adjusting blood flow at the wound site and even suppressing wound healing. The non-genomic effects of testosterone can be used clinically to benefit the patient and the Prolotherapist.*

*This article includes several anecdotes illustrating how testosterone and growth hormone injections have worked in a clinical setting. They demonstrate the advantages of using testosterone and growth hormone to enhance Prolotherapy treatments.*

*Journal of Prolotherapy. 2010;2(4):495-503.*

**KEYWORDS:** HGH, human growth hormone, Prolotherapy, testosterone.

## CLINICAL BACKGROUND

The importance of testosterone in wound healing and tissue repair was first brought to my attention by Allan Banks, PhD. Our discussions of Prolotherapy and how it works led to our considering the possibility that testosterone might be beneficial in the process of wound healing. The significance of this hormone to Prolotherapy never left my mind but when and where to use it eluded me for many years. Finally, after personally receiving many painful injections in my wrists, shoulders, feet and hips, I began to look for a less painful alternative.

In the late 2000s, while trying to decide how to treat some senior patients in their late 80's and early 90's, I decided to try small doses of testosterone and growth hormone, first on my shoulders and later on their shoulders. The pain was considerably less and the results were clinically as good as those achieved when using 50% glucose, glycerin phenol (P2G). By late 2007, I was using testosterone and growth hormone on almost all shoulders and hips with great results and with less pain. Dr. Marc Dubick also began using the combination of testosterone and hGH in 2009 with equally good results. He currently is doing the injections under an institutional review board (IRB). See Dr. Marc Dubick's article in this issue.

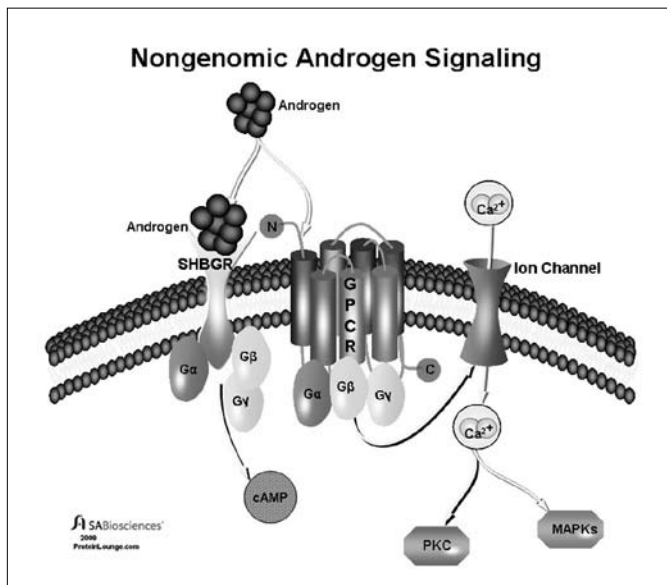
The way Prolotherapy works is probably best explained by the theories of wound healing and tissue repair (inflammation). The book that gathered together the operative ideas in this theory was edited by RAF Clark in the late 1980s.<sup>1</sup> One chapter in that book was written by Allan Banks. This book is still considered to be important reading in the wound healing research world and is still referred to on a regular basis. The last thirty-five years have seen increasingly detailed explanations of this process but no alterations in its basic outline or features. If this is true then the question is: Where and how do testosterone and growth hormone work in stimulating or aiding wound healing and tissue repair?

## SOME BASIC HORMONE CONCEPTS: SIGNALING MOLECULES AND THEIR RECEPTORS

There are many different kinds of molecules that transmit information between the cells of complex multicellular organisms. For now, this discussion is limited to hormones and their effects. Hormone molecules are also known as ligands, which means that they are able to bind to other molecules and form new ones that serve biological purposes. In a narrower sense they are signal triggering molecules that bind to a particular site on a target cell known as a receptor protein. Hormones are secreted by specialized cells and are then carried by the circulatory system to their target organs. They can be produced at the cellular level to affect adjacent cells (paracrine secretion) or by a cell that acts on that cell (autocrine secretion).

To better appreciate how testosterone works it is helpful to understand that there are two types of hormones: steroid and protein. Testosterone is a *steroid* hormone and

hGH is a *protein* hormone. They both share many features such as cell wall receptors. The Androgen Receptor (AR) binds testosterone and testosterone-like molecules called androgens; the Growth Hormone Receptor (GHR) binds growth hormone. These hormones, by way of their receptors, stimulate the transcription of genes into proteins using similar pathways in the cell called “second messenger pathways.” The newly produced proteins control cell function, affect organ systems and affect body functions. These are called genomic effects because they require the decoding of the gene and then the making of the protein. It can take from half an hour to as long as a day for the proteins they stimulate to change the way the target cells react. (See *Figure 1*.)



**Figure 1. The nongenomic effects of testosterone are illustrated here.** Notice the relationship of the G-proteins, G-protein receptor (GPCR) to the ion channel and the MAP kinase pathway. These pathways play an important role in fast cellular responses known as non-genomic signaling. The sex hormone binding globulin receptor (SHBGR) also uses the G-protein to stimulate the cyclic-AMP pathways which supply energy to many other fast acting pathways.

Steroid and protein hormones can also cause what are called non-genomic effects because they cause changes within the cell and its functions in seconds or minutes. These changes are too fast to be the result of gene transcription. It is my opinion that the non-genomic effects of testosterone and hGH are the ones that result following a Prolotherapy treatment, and they are the ones that will be discussed in more detail to follow.

## TESTOSTERONE

The particular focus of this article is on the non-genomic effects of testosterone injected into a new sterile wound site and how testosterone might impact wound healing in the first few minutes of the inflammatory process. These are all non-genomic effects since they occur within the first few minutes.<sup>2</sup> Some of the pathways involved are mentioned in this article to illustrate the degree of understanding of the processes at the cellular level. To learn more about these pathways please see the review articles by Guido Michels and Uta Hoppe and Wikipedia by specific subject.<sup>3</sup> The non-genomic effects have the most relevance to practicing Prolotherapists and are discussed in this article.

## SECOND MESSENGER TRANSDUCTION

Acute wounds create many cytokines and small signaling peptides and most of the immediate changes that we see are using second messenger pathways, which are either the Ca<sup>2+</sup> ion channels or G-protein coupled pathways. We may never need to know the details of these pathways but we will surely be relying on them to understand our treatments. Following, is a brief summary of the two most important second messengers: G-protein and Ca<sup>2+</sup> ion channel.

Second messenger transductions result when androgens outside the cell set off changes within the cell, activating a G-protein. These second messenger G-proteins regulate metabolic enzymes, ion channels, transporters and other parts of the cell machinery, controlling transcription, motility, contractility and secretion.<sup>4</sup> ([www.youtube.com](http://www.youtube.com) video: “G-protein receptors”) These second messenger reactions can be initiated by all the steroid hormones (estrogen, progesterone, testosterone, thyroid and vitamin D), the protein hormones (insulin, prolactin, glucagon, growth hGH), follicle-stimulating hormones (FSH), cytokines (fibroblast, nerve, epidermal, platelet-derived growth factors, etc.), and by many other peptides using their own receptors or sharing the androgen receptor. These are almost all G-protein coupled receptors that lead to the creation of cyclic-AMP, the Mitogen-Activated Protein Kinase (MAPK), tyrosine kinase c-Src and the phosphatidylinositol 3-kinase (PI-3K) pathways.<sup>5</sup> The PI-3K pathway results in lipid products that are known to control cell proliferation, cell survival, many metabolic changes and responses to cytokines.<sup>6</sup>

Modulation of ion channels was one of the earliest observed rapid non-genomic actions of sex steroids. The ion channels are present in the membranes of all biological cells and help control the small voltage gradient across these plasma membranes. Ion channels are classified by gating or what opens or closes the channel. Voltage gated channels open or close depending on the voltage gradient across the plasma membrane. Ligand-gated ion channels open or close depending on the binding of ligands to the channel. Testosterone is able to modulate the intracellular  $\text{Ca}^{2+}$  level within seconds to minutes in different cell systems using both the androgen receptor and non-AR membrane changes.<sup>7</sup> The non-voltage calcium ion channel pathway is a common “second messenger” regulating a wide range of cellular pathways that control the cell response to injury.

#### CELL WALL FLEXIBILITY

The earliest observations that testosterone could alter cellular membranes in the laboratory were made twenty-five years ago. Testosterone in high doses caused the lipophilic or fat loving steroids to interact with cell membrane fats known as phospholipids, changing the lipid-lipid interactions and thereby the cell membrane flexibility.<sup>8</sup> They have been shown to influence cellular adhesion, cell-cell interactions, function of the  $\text{Ca}^{2+}$  ion channels and the effects of cytokines.<sup>9</sup> These cell wall changes have not been researched in greater detail because they only have been observed at supra-physiological doses.

The testosterone doses injected by Dr. Dubick and myself, although only a couple of milligrams and in a small volume, would likely create supra-physiological doses at the injection site at least for a few seconds or a minute. This would explain the powerful effects of testosterone in the first few minutes of wound healing and tissue repair.

#### ACUTE NEURONAL EFFECTS

The use of testosterone appears clinically to decrease the pain of the injections and most patients are able to leave the office without the need for narcotic pain medicine. Many are able to return to work or play even after an aggressive treatment. There is now a scientific explanation for this clinical observation.

The brain and nervous system synthesize steroids that have been given the name neurosteroids. Neurosteroids

have been shown to have a wide variety of functions.<sup>10</sup> The major groups of neuroactive steroids are progesterone, deoxycorticosterone and testosterone. Major targets of these neurosteroids include the ligand-gated ion-channels called GABA<sub>A</sub>, and these steroids also stimulate some intracellular signaling molecules such as the MAPK.<sup>11</sup>

The neurosteroids act specifically at sites that are distinct from the benzodiazepine and barbiturate modulatory sites.<sup>12</sup> There appear to be at least two discrete binding sites in the transmembrane domains of the GABA<sub>A</sub> receptor that mediate the potentiating and direct activation effects of the neurosteroids.<sup>13</sup> Activation of the GABA<sub>A</sub> receptor complex by such neurosteroids resembles, but is not identical to, activation by benzodiazepines and barbiturates, and therefore is capable of alteration of pain thresholds both locally and centrally.<sup>14</sup> Testosterone and the other endogenous steroids are between 10 and 200 times more potent than pentobarbital or benzodiazepines in affecting the GABA-mediated changes in the brain.

The understanding of testosterone’s ability to alter pain and create these changes is less than five years old. Notice the publication dates of all of these references, except one. The developing evidence that testosterone is a key neurosteroid is truly exciting. In the next few years this aspect of testosterone’s non-genomic effects may be clinically of vital importance to Prolotherapists.

#### ACUTE VASCULAR CHANGES

Sex hormones in general, and testosterone in particular, have emerged as important modulators of cardiovascular physiology and pathophysiology. For example, cardiomyocytes have been shown to be testosterone targets.<sup>15</sup> Testosterone replacement therapy improves myocardial ischemia in patients with coronary artery disease, an effect presumably due to testosterone induced coronary vasodilatation. In experimental models, androgens have been shown to exert a specific vascular effect at physiologic levels, and this is direct, non-genomic endothelium independent relaxation.<sup>16</sup> Testosterone increases the local blood supply by changing the voltage-dependent ion-channels. When the coronary arteries are infused with testosterone there is a rapid improvement in myocardial ischemia.<sup>17</sup> These effects are evidenced by the fact that the acute administration of buccal testosterone immediately increases cardiac output, apparently via reduction of left ventricular after load.<sup>18</sup> These studies confirm a rapid non-genomic—mainly vasodilatory—effect of testosterone.

There is now convincing evidence that, at doses used during Prolotherapy treatment, testosterone would alter blood flow at the injection site.

#### TESTOSTERONE SUPPRESSION OF WOUND HEALING

A clinical observation of a gender difference in the pace of wound healing suggests that testosterone may be the culprit. Clinicians fifteen years ago noticed that elderly males healed wounds more slowly than females.<sup>19, 20</sup> The initial studies showed that estrogens accelerated wound repair by dampening local inflammation.<sup>21</sup> More recent evidence has suggested that testosterone is actually a negative or down-regulator of the healing process and leads to a slowed rate of healing of wounds in elderly patients.<sup>22</sup>

It is unclear exactly how testosterone suppresses wound healing and, in particular, how different cell types utilize the cell wall testosterone receptor to regulate wound healing.<sup>23</sup> It seems that all of these cellular responses to wounds use the testosterone receptor and that most use non-genomic pathways.<sup>24</sup> The most important of these down regulatory pathways is increased production of the cytokine TNF- $\alpha$ . because in slow-healing wounds there is a considerable increase in TNF- $\alpha$  at the wound site.<sup>25</sup>

Testosterone seems to be able to either stimulate or suppress wound healing depending on the age of the patient, the part of the wound healing cascade occurring (early or late), the depth of the wound, and the type of testosterone dose – hypo, normal or supra-physiologic. There is little or no evidence at this time that testosterone would suppress the changes at a wound site in the first three to three hundred seconds.

#### GROWTH HORMONE

The addition of hGH to the proliferant solution makes some sense because it is now recognized that growth hormone, and its longer acting sister molecule Insulin-Like Growth Factor-1 (IGF-1), are two important anabolic hormones. They regulate some key metabolic processes and specifically those related to protein synthesis in almost all tissues throughout the lifespan of mammals.<sup>25</sup> Growth hormone is required for normal postnatal growth, having a critical role in bone growth as well as important regulatory effects on protein, carbohydrate, and lipid metabolism. It is an important hormone to supplement in chronic burn patients to help them maintain and gain lean body mass.<sup>26</sup>

The action of hGH is achieved through the stimulation of the Growth Hormone Receptor (GHR) and the stimulation of the IGF-1 pathway and it can happen in many cell types and tissues. The secreted IGF-1 then works in hormonal, paracrine or autocrine ways to modulate many different growth factor and cytokine pathways.<sup>27</sup> Many of the effects of GH on growth and metabolism are actually mediated indirectly via control of the synthesis of other growth factors.<sup>30</sup>

Another key role for growth hormone is the regulation of IGF-1 activity by increasing the production of binding proteins, specifically the Insulin-like Growth Factor Binding Protein-3 (IGFBP-3) that increases the half-life of IGF-1 from minutes to hours. Circulating proteases then act to break up the IGFBP complex, which releases the IGF-1 over time.<sup>28</sup> It seems that hGH and IGF-1 act on different tissue types and operate independently.<sup>29</sup> The addition of hGH to the proliferant injected clinically improves the outcome of Prolotherapy and, when injected with testosterone, enhances the results. The combination of testosterone and growth hormone clinically creates some of the best outcomes, in my experience.

#### CLINICAL EXPERIENCE

In the last twenty-five years of practicing Prolotherapy I have had several goals. One goal has been to get the best results with the fewest and safest treatment sessions, another has been to find the least painful way to treat ligament laxity, and a third has been to find the cheapest path, due to the fact that all of my patients pay cash. It is a given state of affairs in Prolotherapy that it is painful to the patient to receive and it is also uncomfortable for a doctor to have to create pain, but successful Prolotherapy requires the creation of an inflammatory response—*rubor*, *color*, *tumor* and *dolor*, and particularly *dolor*—are a part of the treatment.

I have achieved good results with Prolotherapy using many different kinds of proliferants. I have used just dextrose 30% to 50%, pumice, the combination of glucose, glycerin and phenol (P2G) diluted from 30% to 50%, P2G 50% with 5% sodium morrhuate, needling alone, 70% venous blood and 30% procaine and platelet rich plasma (PRP). All of these injectants have worked and I have gotten from basic, satisfactory results to unbelievable responses with all of them. All Prolotherapists should be getting great results because 60 million years of wound healing and tissue repair are on our side. I have gotten

some of my very best results in treating acute injury by simply refraining from using NSAIDs, encouraging timely and appropriate exercise, and just letting this wonderful process proceed on its own. I have almost always added manipulation, physical therapy, and Pilates, and also have encouraged participation in the activities of daily living to enhance the results.

Getting great results is not the problem; the challenge is how to do it causing less pain and with lower cost. Do I need conscious sedation with its risks and cost? Do I need fluoroscopy or ultrasound to palpate for me with their risks and costs? Do I need PRP when just venous blood might do the job considering the cost difference? As I mentioned previously, striving to cause less pain is about patient comfort.

## Some Case Anecdotes from my Practice

### CASE # 1: CASE REPORT ON MYSELF REGARDING RIGHT SHOULDER PAIN AND TESTOSTERONE

Twenty-five years ago, when I was 44 years old, I fell on my right shoulder while ski race training. I momentarily subluxed the shoulder and got a third degree acromioclavicular joint (ACJ) separation diagnosed in the first aid station. For about three weeks, sleeping was hard and it took 40mg of morphine to even make me comfortable enough to move my arm more than a few degrees, much less use it for basic activities like eating. On day four after the injury, an orthopedic surgical consult was obtained. The physical examination revealed no ability to abduct the arm, minimal internal and external rotation at 25 degrees abduction, a large bruise over the anterior shoulder and a third degree ACJ separation. The situation was discussed with the surgeon and no immediate surgery for either condition was contemplated. (See *Figure 2*.)

The right shoulder remained painful for many months. Throughout the latter 1980s and the 1990s I received some Prolotherapy from various colleagues, most of whom used 50% procaine and 50% P2G. Many of these treatments were so painful that I could not use my arm for 36 to 48 hours and they required a moderate amount of pain medication for one and a half to two days. My shoulder improved considerably with each Prolotherapy



**Figure 2.** Tom Ravin at the Vail Super G, Feb 2010. Just passed the radar gun doing 56.4mph, without any pain.

session and the pain slipped into the background but the weakness in abduction and numbness and tingling when sleeping remained a problem. I continued to ski train and race during the winters and cycled two to three thousand miles per summer. The background pain was an ongoing problem but it was not severe enough to prevent me from participating.

Three years ago I began to explore alternatives to help some older ladies with their shoulder pain. A doctor and upper extremity surgeon from Houston was seeing me for his bilateral shoulder pain, and we began to share stories and ideas about finding and treating sources of our minor but persistent weaknesses and pain. We both agreed that P2G was a painful option and that its tendency to create a lot of swelling limited the amount that could be injected. At the end of one of his treatment sessions in the fall of 2007, I asked him to evaluate my right shoulder. The anterior compression test was 2+/4 weak both the anterior and posterior capsules were 2+/4 TtP (tender to palpation). We decided to do the usual injection sequence; however, we used 10mg aqueous testosterone and 0.5% procaine instead of the usual P2G and sodium morrhuate. (As described in the book *Principles of Prolotherapy*.) Since I had a long experience with the latter combination and the injection sequence, I felt I could accurately evaluate the treatment.

This first treatment was totally different. I noticed several things initially. The pain was a lot less during the injection

and he was able to treat more of each ligament than I had experienced during other treatment sessions. Later that afternoon I noticed the biggest difference. I felt no need for pain medication and, in fact, my shoulder felt stronger. So I continued to treat the two remaining patients as I normally would have. That night I had a couple of glasses of wine with dinner and went to sleep with only 10mg of hydrocodone. Since then I have used only this combination on my shoulders and each treatment has helped me increase the range of motion and the strength. I have had five more treatments by my doctor friend and have worked hard at Pilates. Right now my shoulder is as strong as it was before I fell.

#### CASE # 2

First visit: A 62-year-old female came in complaining of right knee pain. She had fallen twice in a 24-hour period one year prior. Her X-ray was negative for fracture. Initially the pain was minimal and isolated to the anterior medial knee. There was no history of the knee locking. Physical examination initially revealed a 1+/<sup>4</sup> lax medial collateral ligament (MCL) that was tender to palpation (TtP) and a very tender area to palpation just above the anterior medial tibial plateau that reproduced some of the knee pain. The initial diagnosis was a mild medial collateral ligament tear and a bruised knee.

Second visit: Over the next six months the pain became progressively worse and began to extend across the knee involving the peripatellar soft tissues. The pain was then causing disruption to sleep and the patient required one to two hydrocodone tabs to get through the night. The patient returned to the clinic for reevaluation. Physical examination of the medial knee revealed that the MCL had tightened up. The anterior medial joint line still was 3+/<sup>4</sup> tender to palpation. The patellar tendon was 2+/<sup>4</sup> tender to palpation and the posterior lateral corner was 2+/<sup>4</sup> TtP. The diagnosis was a medial meniscus anterior horn horizontal tear and mild patellar tendinosis. The medial meniscus tear was treated with a solution of 1mg of testosterone in 3cc's of procaine using a 27G 1.5-inch needle. The patellar tendon was treated with 4mg of testosterone in 10cc's of 1% procaine using a 22G, 2-inch needle for a total of 3cc's. The patient left the office with a small limp but the medial knee was pain free. The patient later stated she used 5mg of hydrocodone that evening and then did not need any other pain medication.

Third office visit: The patient returned six weeks later stating that there had been some improvement in the patellar pain but essentially no change in the anterior medial knee pain. Physical examination showed the anterior medial knee pain was smaller in size but still 3+/<sup>4</sup> TtP. The meniscus was treated again using the same combination as before and, because the patellar tendon was continuing to improve, it was decided to just watch it. The patient did not use any pain meds during or after the treatment.

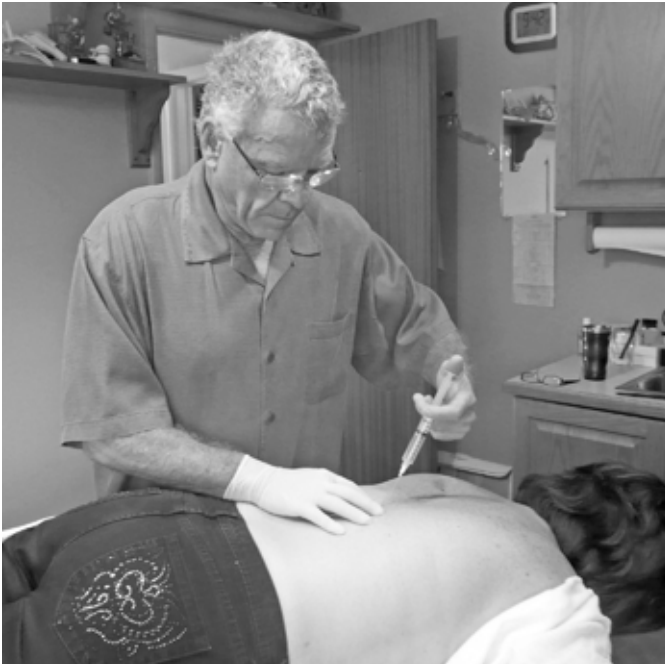The patient related six months later during a phone call that she had no patellar or medial knee pain.

#### CASE # 3

First visit: A 50-year-old female came in complaining of neck pain and headaches. These symptoms had been getting worse over the years but were now interfering with her activities and sleep. She related that the problem may have started about twenty years earlier when she was involved in a whiplash type car accident. She stated that her neck felt unstable and "weak." Physical examination revealed 3+/<sup>4</sup> TtP along the nuchal ridge and the base of the skull. There was bilateral posterior capsular ligamentous laxity with associated mechanical joint dysfunctions at C3-C6. The posterior capsules were 3+/<sup>4</sup> TtP and the pain increased with pressure and stress. The stress of the joints also reproduced some of the pain complaints. The patient was treated with manipulation only. The manipulation resolved most of the pain complaints.

Second visit: The patient returned one week later and stated that the manipulation helped but it only lasted about three days. The physical examination revealed little or no changes in the findings from the first visit. The lack of progress suggested that the problem was tendinosis of the semispinalis and rectus capitus tendons along nuchal ridge and posterior capsular ligaments laxity at C3-C6. The tendon attachments were injected with 1% procaine and 1mg testosterone in a 10cc syringe. The right and left C3 through C6 posterior capsular ligaments were treated with 4mg of aqueous testosterone in a 10cc syringe of 1% procaine. The patient took 5mg of hydrocodone after the treatment, and subsequently, needed no additional narcotic pain relievers. (*See Figure 3.*)

Third visit 12 weeks later: The patient returned stating that her headaches were much less frequent for 8 weeks following the treatment, but had now returned to the



**Figure 3. Dr. Tom Ravin treating a patient's lower thoracic spine with procaine and testosterone.**

point that they were bothering her so she wanted another treatment. Physical examination revealed that the semispinalis tendon and the rectus capitis tendons were 1+/4 tender and the tender areas were much smaller. The lower cervical spine was less unstable and the posterior capsules were only 1+/4 TtP. The treatment was a repeat of the first injection. This time the patient needed no pain medication after the treatment.

At this time she has some residual neck pain complaints but feels that her neck pain is about 80% improved.

#### CASE # 4

First visit: A 42-year-old male came in complaining of left hip pain. The patient is an avid bike rider and over the previous six months the left hip pain had been getting progressively worse, particularly after riding. The left hip pain was tolerable when he was riding but later made it impossible for him to sleep on his left side. Physical examination revealed normal lumbar and sacroiliac joint function. The anterior hip drawer sign was 2+/4 positive and the posterior hip drawer was 2+/4. The capsule was 2+/4 TtP. The examination was discussed with the patient and the posterior ligament laxity demonstrated to the patient. The need for Prolotherapy to the hip was discussed with the patient. The treatment was done on

the anterior, lateral and posterior hip capsule using 5mg of aqueous testosterone in 10cc of procaine in each of the three areas of the capsule. The patient took 5mg of hydrocodone, watched some television and went to bed two hours later without taking more pain medication.

Second visit: The patient returned to the clinic four months later stating that the first treatment had decreased his left hip pain by 50%. His pain complaints had now returned and he thought he needed another treatment. He still was sleeping better but the pain was bothering him after his bike rides. Physical examination revealed a 1+/4 anterior hip drawer sign and a 1+/4 posterior hip drawer sign. The capsule was only tender to palpation both anteriorly and posteriorly. The treatment was a repeat of the first one.

Third visit: The patient returned to the clinic eight weeks after the first treatment and the left hip pain had decreased by 75%. He noticed how much more stable it felt and he had no pain or discomfort sleeping on his left side. Because the biking season was coming and he was still having some pain at the end of his rides, he felt one more treatment was indicated. Physical examination revealed a 1+/4 anterior drawer sign and a 1+/4 posterior drawer. The capsule was only slightly tender to palpation posteriorly. The treatment was a repeat of the first one.

In a follow-up conversation with the patient at twelve weeks he reported that his pain complaints are 90-95% better. He is planning on riding the 120-mile Triple Bypass bicycle ride, which has 9,000 vertical feet of climbing.

#### CASE # 5

First visit: A 41-year-old female came to the office for evaluation of persistent pain near the spine just below the bra line, as well as a chronic headache. The pain started several months earlier when she tried to pick up her five-year-old son. Massage helped some but the relief was short-lived. Physical examination of the spine revealed a T11 vertebra that was rotated to the left and was in extension. Deep palpation over the facet joints, the interspinous and the left costotransverse ligaments reproduced some of the patient's pain complaints. The left 11th rib was posterior to the ribs above and below. Treatment consisted of manipulation of the rib and 11th vertebra. The patient experienced relief of the headache and pain.

Second visit: The patient returned to the office one week later. The headaches and back pain had returned. She related that she had felt good and did not have a headache or backache for two days following her treatment, but then the pain returned. On physical examination the findings were the same as at the first visit. The treatment was manipulation, as she was reluctant to have injections.

Third visit: The patient returned to the office three weeks later. The headaches and back pain were back once again. She had experienced about five days of relief until she picked up a big bag of groceries. The physical exam was the same as on the previous visits. The cause of the recurrent joint dysfunctions (they were the result of ligament laxity) was discussed with the patient. The idea that Prolotherapy could tighten the ligaments was broached with the patient and she thought it was a good idea. Treatment consisted of treating the facet joints at T10 and T11 and the left T11 costotransverse joint with 3mg of aqueous testosterone and procaine. The four facets were each treated with 4cc's of the solution and the costotransverse was treated with 3cc's.

Fourth visit: The patient returned to the office after three weeks. In the last week the patient had experienced only one headache and the mid-back pain was 40% better. Physical examination revealed no vertebral or rib dysfunction. The facets and the costotransverse ligament were only slightly tender to palpation. It was decided that one more treatment would stabilize the situation. The treatment was the same as at the third visit.

Six weeks later I talked to the patient in the grocery store. She had not had a headache since the last treatment and the back pain was gone and she said, "Thank you very much for all you did."

#### CONCLUSION

Testosterone and growth hormone are essential for the growth and development of all mammals. Testosterone and its metabolic derivatives play key roles in regulating cell functions, from stimulating protein production (a slow process called genomic effects) to altering pain in a second or two (called non-genomic effects).

The non-genomic effects all take place within a minute or two of exposure to testosterone and all of these changes probably use some common cellular mechanisms. Second messenger transduction using the G-protein and

Ca<sup>2+</sup> ion channels allows testosterone to respond by producing cytokines and other peptides that help direct acute inflammatory process. Testosterone influences the GABA<sub>A</sub> like receptors in nerves that alter the response to pain signals and their pathways. Testosterone changes vascular tone and blood flow using the voltage-dependent ion-channels. This altered blood flow at the wound site could influence the distribution of cytokines locally and globally.

The use of growth hormone with testosterone enhances the effects of both hormones on the response to wound healing and in fact they may be essential ingredients for good wound healing. They share many common pathways and stimulate the production of common cytokines necessary for wound healing. There is strong scientific evidence that testosterone and growth hormones' major impact is in the first few minutes of wound healing, despite the fact that, so far, the evidence of such mechanisms does not derive from studies directly addressing this particular issue.

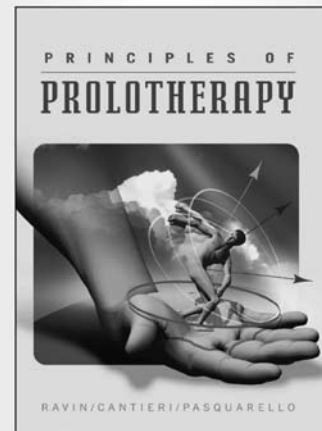
Testosterone in the clinic gives almost as good results as 50% dextrose and glycerin or PRP, and with less pain. Because there is less swelling with testosterone or testosterone with growth hormone, it is easier to extend and expand each treatment and find more of the injured ligament with each treatment session. As I mentioned at the start of this discussion, there are many substances that can be injected into ligaments and provide good to great results, but aqueous testosterone provides a wonderful balance of effectiveness, cost, and pain management. ■

#### REFERENCES

1. Clark RAF, ed. 1996. *The Molecular and Cellular Biology of Wound Repair*. 2nd ed. New York: Plenum Press.
2. Boonyaratankornkit V, et al. Receptor mechanisms mediating non-genomic actions of sex steroids. *Semin Reprod Med*. 2007;25:139-153.
3. Michels G, et al. Rapid actions of androgens. *Frontiers Neuroendocrinology*. 2000;29:182-198.
4. Berridge MJ, et al. Calcium—a life and death signal. *Nature*. 1998;395:645-648.
5. Culig Z, et al. Androgen receptors in prostate cancer. *J Uro*. 2003;170(4):1363-1369.
6. Liu X, et al. The v-Src SH3 domain binds phosphatidylinositol 30-kinase. *Mol. Cell. Biol*. 13:5225-5232.
7. Sun YH, et al. Androgens induce increases in intracellular calcium via a G protein-coupled receptor in LNCaP prostate cancer cells. *J. Androl*. 2006;27:671-678.



8. Van Bommel T, et al. Effects of high-dose medroxyprogesterone acetate and various other steroid hormones on plasma membrane lipid mobility in CAMA-1 mammary cancer cells. *Anticancer Res.* 1987;7:1217–1223.
9. Duval D, et al. Non-genomic effects of steroids. interactions of steroid molecules with membrane structures and functions. *Biochim. Biophys. Acta.* 1983;737:409–442.
10. Hosic AM, et al. endogenous neurosteroids regulate GABAA receptors through two discrete transmembrane sites. *Nature.* 2006;444:486–489.
11. Compagnone NA, et al. Neurosteroids: biosynthesis and function of these novel neuromodulators. *Front. Neuroendocrinol.* 2000;20:211–56.
12. Michels G, et al. GABAA receptors: properties and trafficking. *Crit. Rev. Biochem. Mol. Biol.* 2007;42:3–14.
13. Wilkins ME, et al. Endogenous neurosteroids regulate GABAA receptors through two discrete transmembrane sites. *Nature.* 2006;444:486–489.
14. Fernandez-Guasti A, et al. Anxiolytic-like actions of testosterone in the burying behavior test: role of androgen and GABA-benzodiazepine receptors. *Psychoneuroendocrinology.* 2005;30:762–770.
15. Golden KL, et al. Testosterone regulates mRNA levels of calcium regulatory proteins in cardiac myocytes. *Horm. Metab. Res.* 2004;36:197–202.
16. Yue P, et al. Testosterone relaxes rabbit coronary arteries and aorta. *Circulation.* 1995;91:1154–1160.
17. Jones RD, et al. The influence of testosterone upon vascular reactivity. *Eur. J. Endocrinol.* 2004;51:29–37.
18. Pugh PJ, et al. Acute hemodynamic effects of testosterone in men with chronic heart failure. *Eur. Heart J.* 2003;24:909–915.
19. Ashcroft GS, et al. Estrogen accelerates cutaneous wound healing associated with an increase in TGF- $\beta$  levels. *Nat. Med.* 1997;3:1209–1215.
20. Ashcroft GS, et al. Androgen receptor-mediated inhibition of cutaneous wound healing. *J. Clin. Invest.* 2002;110:615–624.
21. Ashcroft GS, et al. Topical estrogen accelerates cutaneous wound healing in aged humans associated with an altered inflammatory response. *Am. J. Pathol.* 1999;155:1137–1146.
22. Fimmel S, et al. Influence of physiological androgen levels on wound healing and immune status in men. *Aging Male.* 2005;8:166–174.
23. Gilliver SC, et al. Androgens modulate the inflammatory response during acute wound healing. *J. Cell Sci.* 2006;119:722–732.
24. Rahman F, et al. Non-classical actions of testosterone: an update. *Trends Endocrinol. Metab.* 2007;18:371–378.
25. Kuo-Pao Lai, et al. Monocyte/macrophage androgen receptor suppresses cutaneous wound healing in mice by enhancing local TNF- $\alpha$  expression. *J Clin Invest.* 2009;119:3739–3751. Doi:10.1172/JCI39335
26. Demling RH, et al. The stress response to injury and infection: role of nutritional support. *Wounds.* 2000;12:2–14.
27. Fryburg DA. Insulin-like growth factor IGF-I exerts growth hormone- and insulin like actions on human muscle protein metabolism. *Am J Physiol Endocrinol Metab.* 1994;267:E331–E336.
28. Bergad PL, et al. Inhibition of growth hormone action in models of inflammation. *Am J Physiol Cell Physiol.* 2000;Dec;279(6):C1906–17.
29. Goodyer CG, et al. Characterization of the growth hormone receptor in human dermal fibroblasts and liver during development. *Am J Physiol Endocrinol Metab.* 2001;281(6):E1213–20.
30. Butler AA, et al. Control of growth by the somatotropic axis: growth hormone and the insulin-like growth factors have related and independent roles. *Annu Rev Physiol.* 2001;63:141–64. Review.



With more than 250 color photographs and 100 anatomical illustrations, Principles of Prolotherapy provides a comprehensive guide to the body's musculoskeletal anatomy as it pertains to the practice of Prolotherapy.

To purchase visit our website  
[www.principlesofprolotherapy.com](http://www.principlesofprolotherapy.com)

\$300.00 + \$22.95 shipping and handling

45 S. Dahlia St.  
 Denver, CO 80246  
 Tel: 303-270-9191