

FOUR-LEGGED PROLOTHERAPY

Pet Prolotherapy: An Overview and Current Case Studies

Melissa S. Greenberg, DVM

INTRODUCTION

Babette Gladstein, VMD

Melissa Greenberg, DVM, has taken the time to write up for us her numerous cases. What makes these cases interesting is that she is combining the use of PRP (Platelet Rich Plasma) in her therapies. She has given us insight into the popular and up and coming technique that aids in the healing process combined with Prolotherapy techniques. She refers to her therapy as “Regenerative Injection Therapies” that enhances the longevity of the animals she is treating.

She has gone through training with the human side—in properly administering and handling PRP. Her treatments are done in highly controlled office environments. She is finding the time in a busy Veterinary practice to share this information with us all and we thank her for doing so. Her results are conclusively positive.

Recently, with the increased awareness of human regenerative injection therapies (RIT) aka “Prolotherapy,” including platelet rich plasma (PRP) therapy, there has been a surge of interest in the use of these therapies in treating pets for various debilitating conditions. Numerous musculoskeletal pathologies commonly occurring in pets may be successfully treated using these regenerative modalities. This may obviate the need for surgical intervention in addition to the more fundamental benefits of pain reduction and improved quality of life. In veterinary medicine, pets are all too often euthanized as a direct sequella of challenges regarding pain management and joint related morbidity. With appropriate training, veterinarians could incorporate this fairly simple and highly efficacious modality into their practices and dynamically improve the quality of care provided in the

veterinary clinic or home call setting, theoretically adding years to the lives of their cherished pets.

Pet Prolotherapy does present challenges not usually encountered in human medicine. For instance, restraint is required, as is thorough shaving, cleaning, and prepping of injection sites. All pets treated by the author are prepped by clipping of hair around injection sites, thorough washing, and pretreatment with an antiseptic solution such as a quaternary ammonium or alcohol. All use of anti-inflammatory drugs is discontinued a week prior to treatment, or more, depending on the half-life of the particular substance in-vivo. Post procedure, this restriction is continued and pain management is achieved using narcotic analgesics or other non anti-inflammatory class analgesics. It is noteworthy that while this may appear unethical, the inflammatory cascade is crucial in collagen formation. Consequently, anti-inflammatory medications inhibit the regenerative response, thereby decreasing the effectiveness of the procedure.

Due, in part, to the inflammatory ability of the solutions used in RIT, they are considered irritants. RIT is therefore a generally painful process. This necessitates the use of sedation or a light plane of anesthesia in order to achieve the needed level of restraint in almost all animal patients. The author prefers short acting, reversible sedation to minimize the associated risks.

Two basic Prolotherapy solutions were used in the following studies. The intra-articular (IA) injections used a 25% dextrose solution. The peri-articular (PA), tendon and ligament injections used a 12-15% dextrose solution. One percent (1%) procaine, methylcobalamin (B12), and sterile water were routinely included in both formulations. On occasion, MSM, glucosamine and/or Adequan® (polysulfated glycosaminoglycan – IA solution only) were also added to the author’s injection solutions.

Case Studies

CASE # 1: "TOMMY" TERRELL

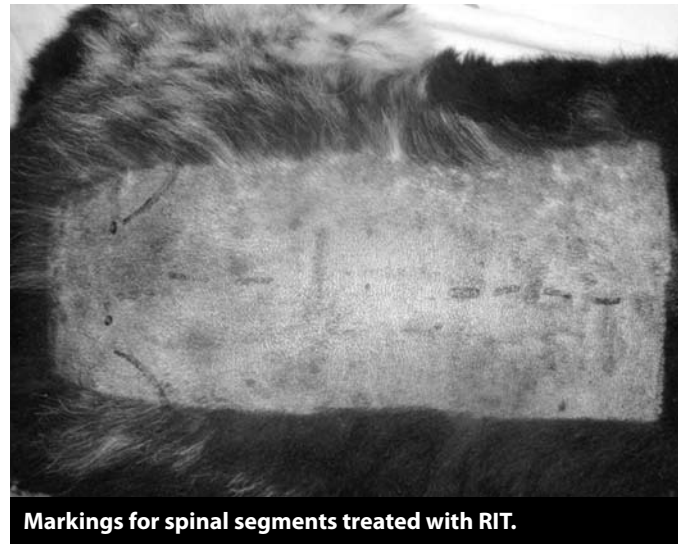
Tommy is an 80 pound, 12 year-old, male, neutered, Australian Shepherd dog. Tommy presented with a three year history of hind limb weakness, ataxia, and lameness. The author was contacted on referral from the owner's own naturopathic physician and as a "last resort." Tommy had been scheduled for full hip replacement surgery prior to his owner contacting the author.

Tommy presented with multiple severe subluxation complexes and muscle spasms from T10-L2. He also had a dramatically exaggerated panniculus response in that region. In addition, there was evidence of degenerative myelopathy of the right hind limb. The pre-treatment exam led to a diagnosis of arthritis (spine and right hip), moderate, as well as hip dysplasia of the right hip, mild to moderate.

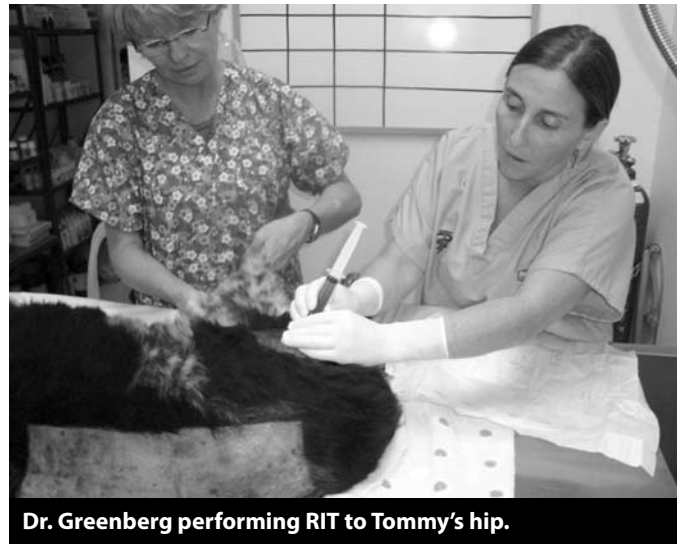Therapy was initiated using adjustments to rehabilitate the innervation to the hip and hind limb. After a series of four to five adjustments with limited lasting progress/relief, the owner elected RIT. Tommy was then treated four times with Prolotherapy.

The initial treatment focused on his hip and right T-L spine segments. IA injections of hip were achieved using a 25g X 2-inch needle. Approximately 8cc of the 25% solution were delivered into the hip joint. PA injections around the hip joint as well as injections on tendonous insertions at the greater trochanter (of the femur), were achieved using 27g X 1-inch needles and the 12.5% solution. Approximately 1-1.5cc was delivered at each site. Injections along the spine included the spinous processes (27g X 5/8-inch), laminae (27g X 1-inch), and transverse processes (27g X 1.5-inch). An excellent outcome was achieved from this first treatment with the pet returning to soundness and increased strength of the right hind limb.

A second treatment was performed two weeks later in order to repeat the spinal segments but on the contralateral side. The author used the same exact procedure with the exception of needle placement which, in this second treatment, was on the left side. The author requires spinal segment RIT to be performed unilaterally in order to avoid the risk of bilateral pneumothorax. Despite the



Markings for spinal segments treated with RIT.



Dr. Greenberg performing RIT to Tommy's hip.

obvious inconvenience of return visits, once educated regarding these risks, clients are happy to comply with this policy.

Approximately four days after the second treatment Tommy was allowed to run off-leash at the beach and swim in water with significant swell. His "over-use" and wave related traumas set him back. Once the initial swelling resolved he was scheduled for a second round of treatments (treatments three and four) approximately a week later, and a week apart. He received treatments three and four, which were repeats of treatments one and two, respectively. A month later Tommy demonstrated improved hind limb coordination, hind limb strength, and increased muscle mass. Notably, he was sound at a walk and run.

CASE # 2: "PAKA" CONDON

Paka is a 57 pound, 4 year-old, female, spayed, Pit Bull mix dog. Paka presented with a two year history of lameness in the hindquarters. On presentation she was noted to be "tripodding" and severely lame on left hind, even when standing still.

Paka presented with multiple severe subluxation complexes from spinal segment T8 through L3. In addition, pre-treatment exam revealed severely decreased range of motion (ROM) in the left hip. Radiographic examination of the affected region confirmed the diagnosis of moderate hip dysplasia at the left hip along with decreased intervertebral disk spaces in the affected area of the spine.

Paka's owner had been referred for adjustments but the author was able to convince her of the utility of concomitant RIT. Prolotherapy was initiated after a few weeks of adjustments which alone had yielded only limited progress.

To date, only three Prolotherapy treatments have been administered. The first treatment was performed only at the left hip. An IA injection as described in case #1 was performed. A total volume of approximately 8cc of 25% dextrose solution was delivered. PA sites were also injected and a 12.5% solution was used to "pepper" the attachment sites around the left hip joint. The insertions at the greater trochanter were treated in a similar fashion. Paka did very well and began using her left hind limb again, albeit cautiously.

The second treatment was performed four weeks later and involved repeating the procedures of the first treatment in addition to addressing the chronicity of the spinal subluxation complexes and compression. Spinal segments T8-L4 were treated in a similar fashion to the treatment described in case #1. Two weeks later Paka's owner reported Paka was "acting like a puppy again" and using her left hind limb regularly and fully!

However, after an episode of over-use, Paka suffered trauma to the joint and a moderate inflammatory response ensued along with a significant setback. Treatment three was performed approximately three weeks after treatment two. The RIT was performed in an identical fashion to that performed in treatment two. Paka's owner was also

re-educated at that time on the importance of limiting Paka's exercise, post treatment. An excellent outcome was achieved.

Due to the severity of Paka's initial presentation in combination with her demeanor (and active lifestyle), it was recommended that PRP be employed for future treatments due to its more aggressive and efficacious action. Her owner has elected to comply with this recommendation. Paka received her first PRP treatment recently and is already demonstrating signs of a successful outcome. Hydrotherapy has also been recommended to augment her recovery.

CASE #3: "ARCHER" ELSON

Archer, a 95 pound, 11 month-old, intact, male, Great Dane dog presented for lameness of two month duration. On exam the lameness was localized to the left shoulder. Left forelimb lameness was further evaluated using radiographs which revealed the diagnosis of osteochondritis dissecans, or "OCD." No joint mouse was detected.

Physical exam revealed tenderness at left shoulder with multiple, regional trigger-points. The author initiated therapy of twice weekly intra-muscular (IM) injections of Adequan®. After three weeks, initial Prolotherapy was performed.

The first treatment consisted of an IA injection of the left glenohumeral joint. The standard 25% dextrose solution was used and approximately 5cc was delivered using a 25g X 2.5-inch needle. Two cc of Adequan® were also delivered directly into the glenohumeral joint. PA injections were then performed using the 12.5% solution. Ligaments and tendonous attachments were injected using a 27g X 1-inch needle. A return to soundness was achieved and owner reported an 80% improvement.

A second treatment was performed approximately six weeks later as Archer's owner was on vacation at four weeks post initiation of therapy. The second treatment was performed similarly to the first with attention being given to remaining tender regions. Approximately one month later, Archer's owner reported a complete resolution of signs and symptoms. Archer subsequently returned to full soundness and has remained so for the last 22 months.

Due to the genetic link noted with OCD, all affected individuals should be neutered. On Archer's second appointment he was neutered before receiving his RIT.

CASE #4: "BABY" TREVOR

Baby is a 65 pound, 5 year-old, female, spayed, Pit Bull mix. Baby presented for hind limb lameness of two year duration. At the time of her initial exam, her owner was questioned thoroughly regarding the possible inciting cause of her lameness. Baby's owner then reported that "Baby loves to play Frisbee." She then continued: "One day about two years ago, Baby leapt approximately five feet into the air after a Frisbee. When she came down, the concrete decking was wet and slippery and as she landed, something went terribly wrong. She lost her footing and yelped loudly. She has been limping like this ever since."

On presentation, Baby demonstrated mild right hind limb lameness. The gait of her right hind limb appeared aberrant and as if she was "walking on egg shells." Physical exam of the right knee revealed no anterior drawer sign but some anterior laxity was present. The knee was tender on palpation and on movement through the ROM.

Palpation revealed a laterally thickened fibrotic joint capsule with probable calcific tendonosis of insertions around the knee. The evidence, while not pathognomonic, was suggestive of a partial thickness, anterior cruciate ligament (ACL) tear with secondary degenerative chondritis and other associated sequellae of the admittedly mild yet chronic instability.

Treatment number one involved an antero-medial approach to the IA space. Prolotherapy injection was performed using a 25g X 1.5-inch needle and a 20% dextrose IA solution. Approximately 4cc were delivered IA at the knee. A 12.5% PA solution was then used with a 27g X 5/8-inch needle and included needle fenestration of the lateral collateral ligament, the tendon of insertion of the quadriceps femoris, and surrounding "tender" structures. All were "peppered" at multiple sites with .5-1.5cc of PA solution.

Three days post procedure, Baby's owner reported that "Baby (was) walking normally." In fact, she quickly resumed her active lifestyle and began to swim and run avidly, once again. Upon follow up examination one month post treatment, the author noted that while she

was dramatically improved, she had not returned to full soundness. A second treatment was then performed using a larger dose (7cc) of a more concentrated dextrose solution (25%). Baby had a difficult time for three days post treatment #2 but had recovered by day four. Approximately one month after the second treatment, Baby was fully sound with no evidence of residual lameness.

Baby's 84 year-old owner's only concern now, is that with Baby feeling so much better, it will be hard for her to keep up!

CASE # 5: "PU'ILI" DEHNE

Pu'ili is a 105 pound, 12 year-old, female, spayed, Rottweiler dog. Pu'ili presented with a five year history of severe arthritis in the hind quarters.

This case is available at www.journalofprolotherapy.com.

CONCLUSION

This combination of therapies (traditional Prolotherapy and the emergent, more aggressive, and efficacious PRP), clearly has a valuable role in veterinary medicine. Not only do they lessen the need for more invasive surgical interventions, they also reliably enhance the quality of life and longevity of the animals treated. It is this author's hope that this data will encourage other practitioners to incorporate these relatively simple yet highly beneficial modalities into their practice of veterinary medicine. ■