



Building a Rationale for Evidence-Based Prolotherapy in an Orthopedic Medicine Practice

Part IV: Diagnosing Linked Prolotherapy Targets by Applying a Data-based Biotensegrity Model

Gary B. Clark, MD, MPA

Patients with sacral dysfunction routinely present sequentially-linked targets for Prolotherapy of varying severity from the plantar arch to the nuchal line.

Part I of this series presented the logical development of Prolotherapy, highlighting Empirical, Deductive, Inductive, and Abductive analytical reasoning (IDEA).¹ Part II discussed the application of the IDEA-based Scientific Method for evaluating Prolotherapy in an Orthopedic Medical setting.² Part III presented a data-based case series study of chronic back pain due to sacroiliac joint dysfunction (SIJD) treated by Prolotherapy.³ Although that study was nonrandomized and uncontrolled, it strongly suggested important clinical correlations supporting and elucidating the nature of the injury—as well as the efficacy of the Prolotherapy.

This, Part IV, employs lessons learned from the Part III case series study to expand the Chronic Back Pain-SIJD-Prolotherapy correlation. In doing so, this article provides a definitive description of clinically applied Biotensegrity. It presents a total body system of potential targets for Prolotherapy consideration—introducing a functional model of tension-compression injuries with a general grading system of Biotensegrity injury severity.

BIOTENSEGRITY

Gravity exerts a constantly compressive force on all tissues: the human body moves through a sea of gravitational compression. All tissues must counter that force with equal or greater biologically-derived tension-compression forces. This complex geo-biological structural balance is termed “Biotensegrity,” as championed by Steven Levin, MD, and adapted from Buckminster Fuller’s “tensegrity,” which is a contraction of “tensional integrity.” The companion to tensegrity is “floating compression,” so labeled by Kenneth Snelson.^{4,5}

Organic structures that facilitate the transferring and stabilization of Biotensegrity tension-compression forces exist at every biological structural level. Those structures form a kinetic chain of interoperative components that extend from individual intracellular structure, to specific tissue composition, to whole organ architecture, on to organ system integration.

The organ system that generates major counter-gravitational Biotensegrity forces is the neuromusculoskeletal system (NMS). A totally integrated NMS facilitates efficient, balanced ambulation and other movement—as well as minimization of compression-related neurological injury—all of which is centered at the joints. Joint tissues comprise the epicenter of a natural struggle at which there is a constant biodynamic flux in the balancing of NMS-derived tension and compression forces against persistent gravitational compression. Osteopathy, Rolfing (Structural Integration), and Pilates have long emphasized the clinical importance of balancing these countering forces.

In an ideally uninjured state of normally functional Biotensegrity, the countering of gravity by ligamentous, muscular, and bony tension and compression is biodynamically balanced and synergistic. In the compromised state of Biotensegrity dysfunction, those NMS forces become unbalanced and dys-synergistic—accompanied by a variable extent of neuroprotective postural adaption. This is clinically manifested by tension-driven NMS soft tissue stretch, stress, strain, sprain, tear, and avulsion with bony tissue osteoneogenesis (i.e., spurring) injuries and compression-driven NMS soft tissue shortening or nerve impingement and bony tissue remodeling, osteoneogenesis, stress fracture, or osteoarthritic injuries.

“Biotension” injury (versus “biocompression”) can be passive or active. Passive biotension injury results from:

1. direct gravitational compressive force on ligaments, e.g., sacroiliac ligament sprain and collapse, or
2. indirect muscular tensional force such as seen in compensatory leg shortening, e.g., Biceps femoris (hamstring) muscle ischial tendinosis of a compensatory functionally shortened leg.

Active biotension injury results directly from muscular force actively causing a compensatory postural change, e.g., Tibialis posterior tendinosis causing adaptive supination in forming a compensatory functionally shortened leg.

Tension-related lesions respond very well to Prolotherapy as a treatment of choice in restoring balanced, functional Biotensegrity. However, passive versus active tendon and ligament lesions may differ in their response to various proliferant delivery systems.

THE SACRED SACRAL BONE AND SACROILIAC JOINT DYSFUNCTION (SIJD)

Since early antiquity, the sacrum has earned the distinction of being the keystone to bipedal NMS form and function. Early Greeks referred to the sacrum as *hieron osteon*; early Latin nomenclature referred to it as the *os sacrum*—in both cases meaning “strong, sacred, or holy bone.”⁶ In pre-Cartesian philosophy, the sacrum was considered the seat of the soul.⁷ In Slavic and German languages, it was referred to as the “cross bone,” (as in “transitional”).⁸ It is clear that the Ancients had deduced that sacral integrity was fundamental to bipedal ambulation and related postural health.

Volumes have been written about the manifold and complex physiologically normal sacral movements. The sacroiliac ligaments (SIL) and their companion iliolumbar ligaments (ILL) bear the burden of supporting those normal sacral movements under the force of gravity. The SIL and ILL comprise a kinetic chain of linked components that extend from one sacroiliac joint (SIJ) to the other SIJ when torquing from one side to the other. In doing so, these ligaments bear at least half of the patient’s body weight from above the waistline. Additionally, these ligaments transfer all of the patient’s weight with every step that we take—as reported in one study, we might take up to 18,000 steps per day⁹—all in a gravitational field.

As with every bone-to-bone-interface, there are the usual physiological restrictions and fixations of sacral movement that can occur within the normal arcs and

ranges of movement. Gravitational force, however, is the proverbial bane to those physiological sacral movements, their weight-bearing sacroiliac ligaments, and their supporting muscles. Thus, a physiological joint restriction can become a pathological subluxation.

Over time, therefore, the wear-and-(literally)-tear of normal sacral joint motion in gravity wages a predictably overwhelming physical toll on the tissues that support sacral form and function. When gravity wins out—and it often does—all of the normal sacral motions can virtually disappear in functional and therapeutic importance. The sacrum can ultimately assume a nonphysiological, side-bending, inferior displacement (i.e., subluxation)—as manifested by inferior displacement of the sacral base and sacral inferior angle and the displaced sacroiliac joint becoming immobile. This pathological sacral displacement is referred to, here, simply as “sacroiliac joint dysfunction” (SIJD), since patients can present with a mixed picture of subluxation that may be preceded by, or might alternate with, more physiological alignment abnormalities within the boundaries of normal range of motion.

SIJD is primarily caused by SIL and ILL sprain injury with resultant ligament incompetence (e.g., lengthening, laxity, weakness). Although a patient presents with unilateral sacral displacement—and, often, with unilateral symptoms—the SIJ sprain lesion is almost always bilateral. This is due to the natural progression of the postural injury—due to the patient repetitively stretching through transitional, partially stressed, partially sprained SIJ and ILL ligaments on the initially extended side (e.g., the right SIL and ILL when rotating to the left) to the “end-organ,” fully stressed, fully sprained SIJ ligaments on the farthest extended side (e.g., the left SIL and ILL when rotating to the left), as illustrated by Ravin, et al.¹⁰

Right-handedness is found in 70-90 percent of the world population.¹¹ Right-handedness causes preferential turning to the left, which is correlated with right cerebral hemispheric dopamine predominance.¹² Of the 54 study patients requiring Prolotherapy in the Part III study, all were right-handed. There were no left-handed patients—they seemed to have been virtually spared. Could being left-handed in a right-handed world provide some protective balancing of tension-compression Biotensegrity and gravitational forces? It appears possible, especially when applying a functional Biotensegrity model, as described in this article. The relevance of right versus left-handedness to SIJD needs further study.

Also shown in the Part III study, SIJD became evident by the average age of 43 and 45, female and male, respectively.³ However, the ratio of females to males was 3 to 2 and females presented as early as their mid-teens (i.e., 14 years) whereas the youngest male was 26 years old. Increased female propensity for SIJD was associated with increased signs of general ligament laxity (e.g., earlier onset of Pes planus, multiple joint hypermobility, and multiple sprain injury). Estrogen, progesterone¹³ and relaxin¹⁴ hormone-derived and familial genome-derived general ligament laxity have been observed to confound the natural forces of Biotensegrity, upsetting the delicate balance between biologically-derived tension and compression forces. Thus, such “ligament lax” individuals tend to experience a greater incidence of tension-related stretch, stress, strain, sprain, tear, or avulsion injury and compression-related shortening, impingement, erosion, or impact injuries.

Summarizing, the following forces can cause injury to sacroiliac and iliolumbar ligaments:

- Primarily, life-long weight-bearing and transfer of gravitational and Biotensegrity forces.
- Life-long low back postural torquing force from repetitive rotational twisting of the low back at the lumbar-sacral junction from one side to the other—possibly accentuated by right-handedness.
- Secondarily, decompensatory postural habits secondary to Biotensegrity imbalance remote to the sacroiliac joint—e.g., secondary to Pes planus.
- Traumatic force directly delivered to the sacrum, e.g., falling onto the sacral-ischial anatomy, or indirectly through the legs—e.g., falling onto the feet and legs, experiencing excessive traction on a leg.
- Traumatic force directly delivered to the sacrum from the vertebral column and upper body—e.g., falling onto the upper body, heavy weight lifting—all aforementioned primary and secondary forces being potentially accentuated by general ligament laxity.

In the Part III study,³ 54 patients presenting with back pain and unilateral SIJD required Prolotherapy for stabilization. Forty four (81%) of those requiring Prolotherapy presented with Left SIJD (LSIJD). Ten (19%) patients presented with the mirror-image Right SIJD (RSIJD).

Using the LSIJD patients as an example, the sacrum—by general definition—was non physiologically side-bent and displaced (i.e., subluxed) inferiorly on the left while rotated anteriorly to the right at both its left base and inferior angle. (See Figure 1.) This subluxed left SIJ was markedly restricted in motion. The left ilium—as found in 93% of cases in the Part III study—was flexed anteriorly and the right ilium extended posteriorly. The causative SIL and ILL ligament sprains often generated left-to-central low back pain with variably referred pain to the left buttock, hip, groin, or down the left leg, mimicking sciatica.

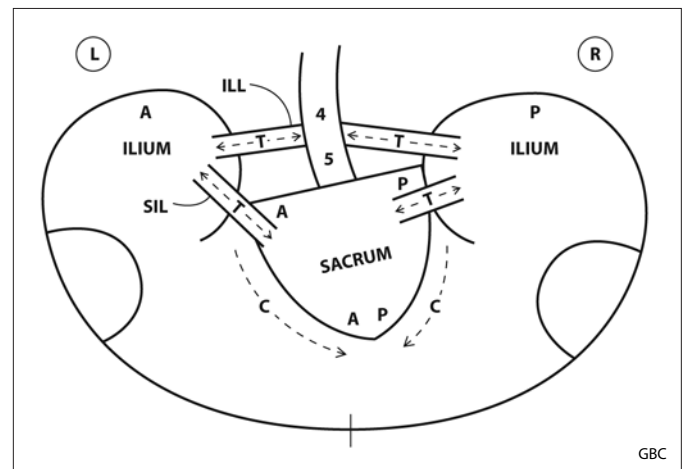


Figure 1. Left sacroiliac joint dysfunction (LSIJD). Schematic showing tension and compression related, potentially injurious, Biotensegrity forces. The SIL and ILL sprains are passive tension (T) injuries. The left sacral inferior angle and sacral base are displaced inferiorly, representing compression (C) injury. L = left; R = right; A = anterior; P = posterior; SIL = sacroiliac ligament; ILL = iliolumbar ligament; 4-5 = lumbar spine.

Potential Prolotherapy Targets in LSIJD: In the Part III study,³ 23 (30%) of the initial 77 male and female patients responded to OMT sacral stabilization, alone. The other 54 (70%) patients failed to respond to OMT and required bilateral Prolotherapy to ultimately stabilize the sacrum. Therefore, definitive treatment of LSIJD consists, first, of OMT applied to the sacrum, iliac bones, and vertebral column. If the sacrum remains unstable after OMT, then those patients deserve treatment by appropriate Prolotherapy of the following, underlying tension-related injuries—bilaterally:

- **The iliolumbar ligament (ILL) at the proximal (transverse processes of L4 and L5) and distal (superior anterior medial iliac crest) bony attachments**

- ***The short posterior sacroiliac ligament (SIL) at the proximal sacral and distal iliac superficial fiber and deep fiber bony attachments***
- ***The long posterior sacroiliac ligament, if painful and tender, at its proximal attachment to the inferior posterior superior iliac spine.***

Severity Grading: Biotensegrity lesions requiring only OMT or Prolotherapy treatments to reach overall normal sacral, vertebral, and lower extremity stability in all kinetic chains are generally graded as *Grade I of IV* in severity.

RSIJD forms a mirror-image of sacral and pelvic displacements in abnormal form and function. Patients with RSIJD routinely present with the exact same Prolotherapy targets and grading severity—they are usually just reversed left to right in degree of severity of ligament injury. Remember that these are usually bilateral lesions.

THREE COMPENSATORY KINETIC CHAINS

SIJD with its unlevel sacral base can create tension-related stretch, stress, strain, and sprain joint injuries, compression-related joint injuries, dysfunction, and pain that can be distributed along three related kinetic chains of neuromusculoskeletal structures. Each kinetic chain extends from the site of primary sacral injury through multiple sites of secondary, compensatory NMS injuries to the end of that physical rotational moment of Biotensegrity tension-compression influence.

In the Part III study,³ LSIJD was found to universally demonstrate three specific kinetic chains:

- Compensatory lumbar levoscoliosis (CLLS) accompanied by a thoracic dextro and cervical levoscoliosis—extending from the primary sacral injury through a scoliotic vertebral column to the nuchal line
- Left functionally short leg (LFSL)—extending from the primary sacral injury through a functionally short leg to that plantar arch
- Right functionally long leg (RFL) —extending from the primary sacral injury through a functionally long leg to that plantar arch.

In the same study, RSIJD was universally found to demonstrate the mirror-opposite patterns—i.e., compensatory lumbar dextroscoliosis, right functionally short leg, and left functionally long leg. In any case, the three secondary subpatterns of SIJD offer a wide spectrum of Prolotherapy-rich diagnostic and therapeutic targets of potentially great importance—from the plantar arch to the nuchal line.

KINETIC CHAIN I: COMPENSATORY SCOLIOTIC VERTEBRAL COLUMN

In the sitting or standing neutral position, the vertebral column normally rises plumb vertically from the normally level sacral base. During normal ambulation, however, the sacral base alternately shifts from level to unlevel from one side to the other, dropping slightly to the side of the unweighted leg in each early swing phase. The iliac bones synchronously and alternately rotate with the iliac bone of the unweighted leg flexing anteriorly in the early unweighted swing phase and the opposite iliac bone extending posteriorly in the early weighted stance phase.

Importantly, as a result of the alternating sacral base orientation during ambulation, the lumbar vertebrae alternately side-bend toward the weighted side and rotate anteriorly toward the opposite, unweighted side in normal, coupled Type I motion. The thoracic vertebrae synchronously alternate in their side-bending toward the unweighted side and rotating anteriorly in normal, coupled Type I motion toward the weighted side. The cervical vertebrae alternately side-bend and rotate anteriorly to the same side in coupled Type II motion—both side-bending and rotating toward the weighted side. Thus, during normal ambulation, the three vertebral sections alternately “undulate” from levo to dextro “normoscoliosis” with each right to left weight-bearing step—side-bending and rotating as a synchronized, balanced kinetic chain of joints from the sacral base and iliac crests (i.e., the inferior NMS anchor point) through all the vertebrae up to the occiput and extending by the suboccipital musculature to the occipital nuchal line (i.e., the superior NMS anchor point).

In comparison, patients with the sacral changes of LSIJD develop a fixed compensatory lumbar levoscoliosis (CLLS) due to the fixed, inferiorly displaced, left sacral base. And, the thoracic and cervical vertebral segments develop their fixed dextro and levoscoliotic arcs, respectively. This nonphysiological deformity is characterized by persistent

dysfunction with the patient often pointing directly at T12 as the source of “weird” discomfort. As explained below, hypertonic, spasmed *Quadratus lumborum* muscles can significantly add to this L1 to T11 dysfunction. This L1 to T11 vertebral dysfunction often persists after successful restabilization of the sacral base.

Along the thoracic spine region from T10 to T1, the vertebral column forms a thoracic dextroscoliotic arc with right vertebral (Type I) rotation. On the right convex side of that thoracic segment, there are the typical passive tension-related chronic stretch, stress, strain, and sprain injuries of ligaments and muscles and facet degenerative changes. On the left, concave side, there are the typical compression-related injuries with active tension. Again, nerve root impingement and/or compression fracture may result, predominantly on the left concave side.

Along the vertebral segment, variably, from about T3 to T5, the persistent thoracic dextroscoliotic left side-bending provokes an accentuated right vertebral rotation, all of which provokes right costovertebral joint and rib posterior displacement with associated ligament and muscle stretching and sprain injury along that passive tension-related convex arc. Often, the result is persistent right interscapular discomfort and pain with a discernible, tender, right paravertebral, parascapular, kyphoscoliotic hump caused by the posteriorly displaced costovertebral joints and ribs.

Along the cervical spine region, the vertebral column is involved in the last, usually milder, cervical levoscoliotic arcing with left vertebral (Type II) rotation—which finally positions the head over the body’s newly adjusted center of gravity. On the left, convex side, there are the typical passive tension-related chronic stretch, stress, strain, and sprain injuries of ligaments and muscles with facet degenerative changes. On the right, concave side, there are the typical compression-related injuries with active tension extending up to the nuchal line. Again, nerve root impingement and/or compression fracture may be an end result, especially on the right, concave side with sensory or motor symptoms often being referred to the right arm.

The more extreme mobility demands made on the neck can create an increased likelihood of manifesting scoliotic stress on susceptible neck tissues. The shortened, actively tensioned paraspinal and suboccipital muscles on the

right, concave side of the neck are particularly prone to stretch, stress, strain, sprain, and spasm after repetitive side-bending and turning. Consequently, the suboccipital muscles, particularly, often are tender at their vertebral and nuchal line attachments causing chronic tension neck pain and headaches that can radiate over the head often to the ipsilateral eye or TMJ. These cervical tension-compression injuries can be aggravated by other factors, such as occupational or training positional-postural stress, shoulder injury, accidental whiplash—and even *Pes planus*, very remotely.

The *Quadratus lumborum* (QL) arises by aponeurotic fibers from the iliolumbar ligament and directly from the adjacent, posterior-medial iliac crest and inserts onto the inferior margin of the twelfth rib and the transverse processes of L1 to L4. In LSIJD, the left *Quadratus* is actively recruited to left side-bend the lumbar vertebral segment as a correction of the lumbar levoscoliotic right side-bending and to lift the left ileum—and, indirectly, the left sacral base—in the unweighted left leg swing phase. This action helps to partially straighten (i.e., decompress) the lumbar concave arc and minimize potential nerve impingement injuries along that lower right lumbar concavity when the left leg is unweighted. Over time, chronic *Quadratus* activation can result in QL muscle shortening, trigger point generation, decompensatory spasm, degenerative tendinosis, and debilitating pain. The right QL, also, is usually posturally and actively shortened, being located within the concave lumbar arc—thus, also easily stressed, strained, and sprained. As aforementioned, either hypertonic, spasmed QL can aggravate the symptoms of restrictive movement along the abnormal T11-L1 segment.

As another compensatory postural adaptation to the unlevel sacral base and resultant scoliosis in LSIJD-CLLS, the right shoulder is often dropped lower and can be more anterior than the left—as seen in 34 (63%) of 54 Prolotherapy cases in the Part III study. This is due to chronic activation of the posterior oblique sling, which consists of the right *Latissimus dorsi* and left *Gluteus maximus* muscle connected via the midline thoracolumbar aponeuroses. Chronic sling activation in the early to mid unweighted left leg swing phase assists in lifting the left sacral base, but often results in muscle shortening, trigger points, spasm, tendinosis, and pain of the two sling muscles.

A chronically shortened right Latissimus dorsi (LD) can aggravate active tension-related tendinosis at its attachment to the floor of the right humeral intertubercular groove (bicipital groove) and a chronically shortened left Gluteus maximus can aggravate active tension-related tendinosis at its attachments to the ilium or greater trochanter. Chronic humeral internal rotation by the shortened LD can be accompanied by recruitment of Subscapularis internal rotation in assisting the sling compensatory effort and cause active tension-related tendinosis of the Subscapularis attachment to the lesser tubercle—as well as there occurring chronic passive tension-related sprain of the posterior capsular ligament and conjoining muscle tendons. Chronic dropping (lowering) of the shoulder effectively increases the angle of resting abduction, which increases the exposure of the Supraspinatus, Infraspinatus, Subscapularis, and long head of the Biceps to impingement injury—as well as labral and other articular injuries of chronic shoulder joint misalignment.

Potential Prolotherapy Targets in CLLS: Definitive treatment of patients with CLLS consists, first, of OMT and Prolotherapy of the underlying LSIIJD tension-related injuries. All patients who remain symptomatic of CLLS-related injuries deserve assessment of additional Prolotherapy of the following *potential* tension-related injuries:

- ***L1 through L5 interspinous ligament, intervertebral facet joint ligament, and paraspinal and Quadratus lumborum tendon attachments, particularly along the left, convex lumbar arc***
- ***Generally, all T1 through T12 interspinous ligament, intervertebral facet joint ligament, and paraspinal tendon attachments, particularly along the right, convex thoracic arc***
- ***Specifically, T11 through L1 interspinous ligament, intervertebral facet joint ligament, and laminar tendon attachments on both sides along the T12 crossover zone***
- ***Specifically, T3 through T5 interspinous ligament, intervertebral facet joint ligament, laminar tendon, and costovertebral joint ligament attachments, particularly along the right, convex thoracic arc***
- ***Cervical spine interspinous ligament, intervertebral facet joint ligament, and laminar***

tendon attachments, particularly along the left convex cervical arc from C7 through—but not above—C3; it is generally dangerous territory above C3, requiring advanced injection technique

- ***Superficial and deep superior and inferior nuchal line suboccipital tendon attachments, particularly on right side***
- ***Left Quadratus lumborum attachments to the iliac crest and transverse processes of L1 through L4***
- ***Left posterior oblique sling tendon attachments, e.g., Latissimus dorsi and Gluteus maximus muscles***
- ***Rotator cuff tendon attachments—e.g., Subscapularis, Supraspinatus, Infraspinatus, and long head of the Biceps muscles—as well as superior labral and posterior capsular ligament attachments.***

While treating these potential target sprain injuries of CLLS by OMT and Prolotherapy, a concerted effort is required to rehabilitate the entire scoliotic vertebral column, including its supportive fascia, ligament, musculature, and osseous components. This should include Neural Therapy of muscle trigger points; Roling (Structural Integration) to balance myofascial length and strength; Pilates to balance and increase upper and lower body core strength and movement; Physical Therapy to treat specific, persistent NMS dysfunctions; and/or Orthotic treatment of coexistent Pes planus to eliminate any pronation-external rotation effect through either of the two lower extremity kinetic chains. One must remember that what has usually taken the patient years or, even, decades to develop often takes months to years of patient rehabilitation to resolve, including the vertebral remodeling.

Severity Grading: Biotensegrity lesions characteristic of CLLS are generally graded as *Grade II of IV* in severity.

Compensatory lumbar dextroscoliosis (CLDS), routinely found in RSIJD, presents with the mirror-image opposites of tension-compression injuries and equal grading severity requiring consideration of treating those injuries with appropriate Prolotherapy.

KINETIC CHAIN II: COMPENSATORY FUNCTIONALLY SHORT LEG

A compensatory left functionally short leg (LFSL) characteristically occurs with LSIJD. The physical causes of functional leg length discrepancy are manifold and can be attributed to Biotensegrity forces acting from above and/or below the level of the lumbar-sacral joint. The dropped left sacral base; left iliac (anterior) flexion; and the lumbar right side-bending with left rotation of compensatory dextroscoliotic L4 and L5 vertebrae seen in LSIJD—each alone or combined—can result in a left functionally shortened leg. However, the presence of an unlevel sacral base can be counted as the primary cause until it has been rectified. The leg can be anywhere from 2 to 15 or more millimeters functionally short. A truly anatomically short-long leg is very uncommon and needs to be confirmed carefully with exact radiological leg length measurement.

The major Biotensegrity dysfunctions inherent in LFSL are consequent to the patient's unconscious, automatic effort to biomechanically lengthen that functionally shortened left leg—and physically raise the dropped left sacral base to reduce right lumbar nerve compression—by actively extending, plantar flexing, and internally rotating (i.e., supinating) the left foot and ankle with each left step at the time of heel strike. This abnormal posturing of the lower extremity can cause multiple passive tension-related stretch, stress, strain, spasm, sprain, and tear injuries along the dorsolateral foot, lateral ankle and knee, and posterior-lateral hip joints.

The counter Biotensegrity forces of compression and active tension adversely affect the corresponding posteromedial aspects of the functionally short lower extremity from the plantar arch to the hip. Compression on the medial aspect of all lower extremity joints causes relative sparing of medial ligaments and muscles from tension-related sprain injuries. (See Figure 3.) These Biotensegrity lesions comprise what has been labeled as the “Short Leg Syndrome.”

At the left foot, constant passive, dorsilateral, tensional stretching from compensatory, adaptive supination can ultimately result in chronic passive tension-related sprain injury of dorsolateral foot ligaments and passive tendinosis at the Peroneus brevis and longus tendon lateral foot attachments. In the more extreme case, there is a predilection for occurrence of unilateral Lisfranc cuneiform-second metatarsal plantar ligament sprain

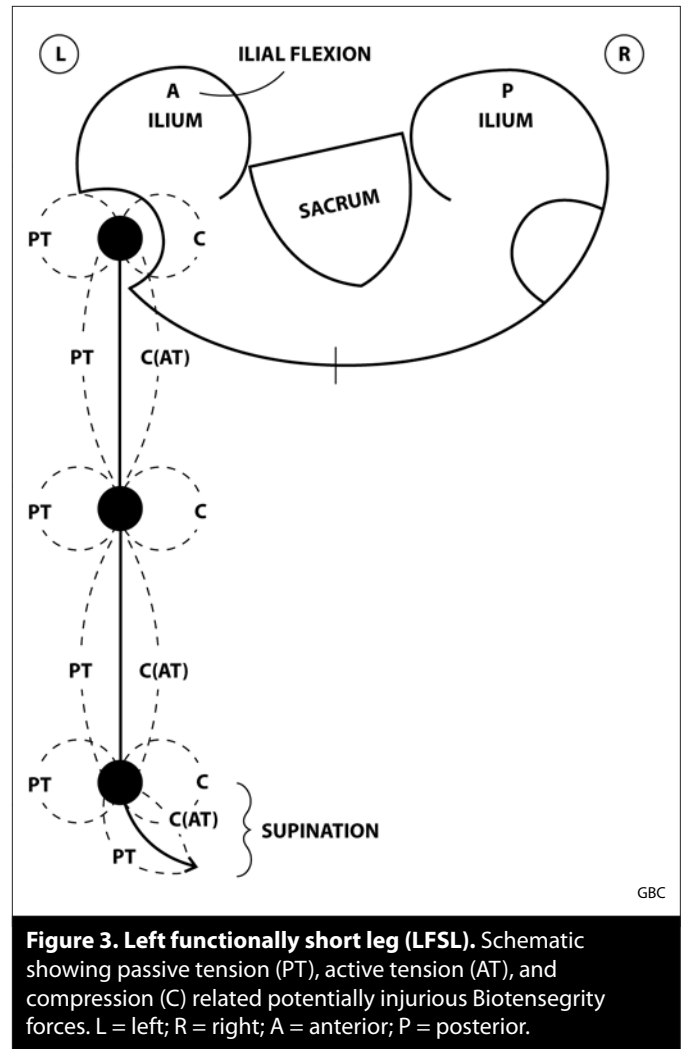


Figure 3. Left functionally short leg (LFSL). Schematic showing passive tension (PT), active tension (AT), and compression (C) related potentially injurious Biotensegrity forces. L = left; R = right; A = anterior; P = posterior.

injury and deformity of the left midfoot, as well as Morton's neuroma between the third and fourth intermetatarsal joints of the left forefoot.

The usual sequelae of Pes planus (e.g., flattened arch Hallux valgus and bunion) are often relatively spared compared to the other foot. In fact, the left foot may take on the unweighted appearance of being more varus, cavus, and internally rotated than the right (i.e., supinated) due to postural remodeling during chronic intermittent supination while ambulating. Chronic activation of the Tibialis posterior in its repetitive attempts to raise (plantar flex) and invert the flattened arch can also cause active, tension-related degenerative tendinosis at its medial and plantar midfoot tendinous attachments.

Posterior column and plantar-wise, chronic, active compensatory shortening of the hamstring-gastrocnemius-Achilles tendon-plantar fascia kinetic chain occurs during

the chronic intermittent supination. This chronic active intermittent posterior column shortening acted upon by the tension generated on stance phase toe off may result in left lateral plantar fasciosis and Achilles tendinosis—as well as left ischial tendinosis remotely proximal at the left ischial tuberosity.

The compression-related impact upon left heel strike, compounded by the posterior column and plantar shortening and tension, can easily aggravate the already stimulated tension-related left lateral plantar fasciosis and Achilles tendinosis. Compression-related metatarsal stress fractures may also occur.

At the left ankle, constant, active tensional stretching often results in lateral ankle ligament stretch, stress, strain, sprain, and even avulsive injuries. Such an ankle can adopt a varus deformity and is particularly prone to inversion sprain accident and injury consequent to the chronic supination at heel strike. Chronic medial compression upon heel strike impact can result in medial ankle-foot joint degenerative arthritic changes.

At the left knee, Genu varus can occur with passive tension-related stress along the lateral aspect often results in predominant sprain injury of the lateral knee ligamentous structures, including the fibular (lateral) collateral, lateral coronary, and posterior lateral corner ligaments. Corresponding displacement of the proximal fibular head also can occur due to capsular ligament sprain injury. The left posterior cruciate ligament is relatively spared injury from any accentuated knee internal rotation-lateral tension due to its relatively short span and substantial strength—but there is always a possibility.

At the left patella, chronic intermittent supination and internal rotation of the distal lower extremity exert a medial compression-related force on the patella, forcing it to the lateral side of its intercondylar groove. This lateral patellar misalignment can result in symptoms of predominantly lateral retropatellar chondromalacia—and may be potentially confused with an abnormal Q angle and mistreated surgically. Chronic medial compression at the knee also can result in accentuated erosion of the medial condylar articular cartilage surface with symptoms and signs of accelerated medial osteoarthritis. Additionally, chronic shortening of the posterior muscular column due to chronic supination can result in compensatory, active tension-related, left quadriceps strain and sprain

and left patellar and quadriceps tendinosis (unilateral jumper's knee). This unilateral presentation is similar to the bilateral jumper's knee presentation seen in bilateral Pes cavus without SIJD.

At the left hip, chronic supination and internal rotation exert chronic passive tension-related forces to the posterior lateral hip capsular ligament and the hip external rotator muscle (i.e., Gluteus maximus, Piriformis, Gemelli, Obturator femoris) tendon attachments. Chronic intermittent activation of the internal rotators (i.e., Gluteus minimis and medius and Tensor fascia latae)—and the aDductors—may produce easily stimulated spasm, trigger points, and a degenerative tendinosis at those tendinous attachment sites—often confused with and mistreated steroidally as trochanteric bursitis.

Potential Prolotherapy Targets in LFSL: Definitive treatment of patients with LFSL consists, first, of OMT and Prolotherapy of the underlying LSIJD and CLLS injuries. All patients symptomatic of LFSL deserve assessment of additional Prolotherapy of the following tension-and-impact-compression-related injuries:

- ***Dorsilateral, plantar left foot ligament attachments—e.g., calcaneocuboid (bifurcate), dorsal calcaneonavicular, talocalcaneonavicular (in sinus tarsi), cuneiform-second metatarsal (Lis Franc), and 3rd to 4th intermetatarsal (Morton's) ligaments***
- ***Lateral left foot Peroneus (Fibularis) brevis tendon attachment to the fifth metatarsal head***
- ***Plantar left foot fascia-ligament attachment to the lateral and mid-calcaneus***
- ***Medial left foot Tibialis posterior tendon attachments, particularly at the navicular***
- ***Lateral left ankle ligament attachments—e.g., anterior and posterior talofibular and calcaneofibular ligaments***
- ***Left Achilles tendon attachment to the left calcaneus***
- ***Lateral left knee and fibular ligament attachments—e.g., fibular-collateral, lateral coronary ligaments, posterior lateral corner ligaments***
- ***Left posterior cruciate ligament attachments—possibly***

- **Left Quadriceps and patellar tendon attachments to patella and tibial tubercle**
- **Treating the sacrum, lateral knee structures, and whatever Pes planus exists by Prolotherapy and orthotic therapy help to correct patellar lateral misalignment and reduce medial plateau compression**
- **Left hamstring tendon attachment at the left ischial tuberosity**
- **Posterior-lateral hip capsular ligament attachments**
- **Lateral hip external rotator tendon attachments—e.g. Piriformis, Gemelli, Obturators, Quadrator femoris)—along the posterior-superior greater trochanter**
- **Lateral hip internal rotator and adductor tendon attachments—e.g., Gluteus minimis and medius and Tensor fascia latae—along the external iliac crest and antero-lateral surface of the greater trochanter.**

Severity Grading: Biotensegrity lesions characteristic of LFSL are generally graded as *Grade II of IV* in severity.

Compensatory right functionally short leg (RFSL), routinely found in RSJJD, presents with the mirror-image opposites of tension-compression injuries and equal grading severity requiring equal consideration of treating those injuries with appropriate Prolotherapy.

KINETIC CHAIN III: COMPENSATORY FUNCTIONALLY LONG LEG

A compensatory right functionally long leg (RFLL), by definition, coexists with the left FSL in patients with LSJJD. It usually results from there being a persistently elevated right sacral base with right iliac extension and lumbar levoscoliosis/left vertebral rotation.

The major Biotensegrity dysfunctions in RFLL are consequent to the patient's unconscious, automatic effort to biomechanically shorten that functionally long leg by actively pronating and externally rotating the foot and ankle, thereby physically flattening the plantar arch. This also effectively helps to lower the high side of the unlevel sacral base and reduce the threat of nerve compression along the levolumbar concave arc. This dysfunctional

lower extremity posturing can cause multiple passive tension-related stretch, stress, strain, spasm, sprain, and tear injuries along the medial aspect of the right foot, ankle, knee, and anterior-medial hip. In parallel, there are counter Biotensegrity forces of compression and active tension impacting on all lower extremity lateral-posterior compartment tissues. Compression on the lateral aspect of all lower extremity joints causes relative sparing of the lateral ligaments and muscles from tension-related sprain injuries. (See Figure 4.) These Biotensegrity lesions comprise a “Long Leg Syndrome,” which is equally as important as its “short leg” counterpart.

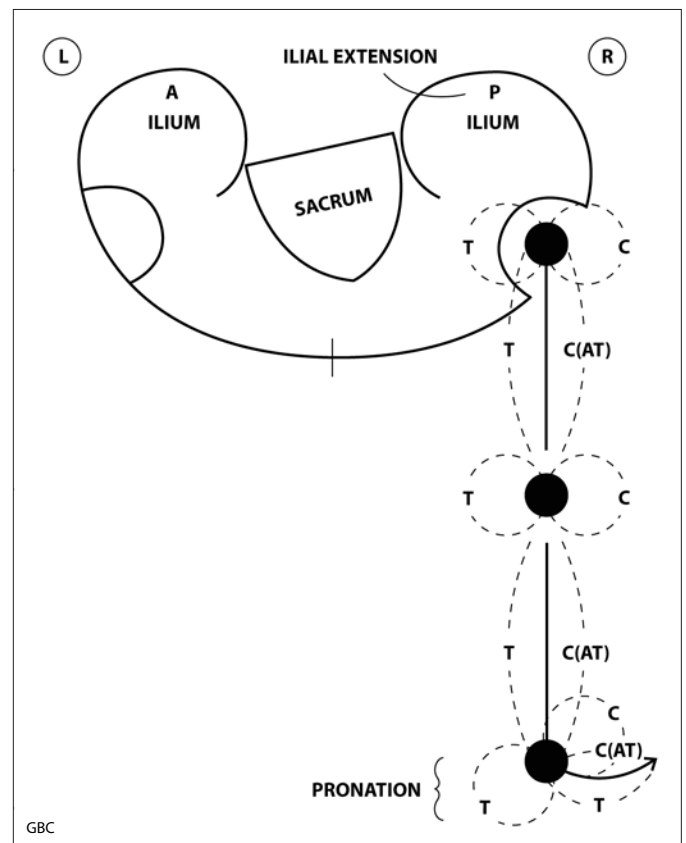


Figure 4. Right functionally long leg (RFLL). Schematic showing passive tension (PT), active tension (AT), and compression (C) related potentially injurious Biotensegrity forces. L = left; R = right; A = anterior; P = posterior.

At the right foot, constant medial, chronic passive tensional stretching due to excessive unilateral pronation can ultimately result in stretch, stress, strain, sprain, or tear injury of medial plantar ligaments and passive tendinosis of the Tibialis posterior tendon medial and plantar attachments. The usual sequelae of Pes planus (e.g., flattened arch, Hallux valgus, and bunion) are often

relatively accentuated compared to the other foot, as well as persistent external rotation in the supine position; unilateral Hallux limitans or rigidus also can result. Chronic intermittent activation of the Peroneus brevis to evert the foot can also cause active tension-related degenerative tendinosis at its lateral foot insertions.

Abnormally directed heel strike impact of the chronically actively pronated-externally rotated right foot-ankle along with a chronically passively stretched medial arch ligament, plantar ligament, and Achilles tendon architecture can aggravate compression-related medial plantar fasciosis. Chronic lateral compression with heel strike impact can result in lateral foot-ankle joint degenerative arthritic changes.

At the right ankle, constant passive tensional stretching predominantly results in medial ankle ligament stretch, stress, strain, and or sprain injuries. Such an ankle can adopt a valgus deformity and is prone to eversion sprain accident and injury. Compression-related articular injury is predominantly found on the lateral side.

At the right knee, Genu valgus can occur with chronic passive tension-related stress along the medial aspect often results in sprain injury predominantly of the medial knee ligamentous and muscular components, including the medial collateral and medial coronary ligaments and the Popliteus, Semimembranosus, and Pes anserinus tendinous tibial attachments. The right anterior cruciate ligament also is at an increased risk of passive tension-related sprain, especially during accentuated foot-ankle pronation-external rotation-eversion.

Chronic pronation and external rotation of the distal lower extremity and resulting lateral compression tend to force the patella to the medial side of its intercondylar groove. This medial patellar misalignment can result in symptoms of predominantly medial retropatellar chondromalacia—and may be potentially confused with an abnormal Q angle and mistreated surgically. Chronic lateral compression at the knee can result in selective erosion of the lateral condylar articular surface. This can result in symptoms and signs of osteoarthritis predominantly on the lateral condylar surface. This unilateral presentation is similar to the bilateral knee presentation seen in bilateral, severe Pes planus without SIJD.

At the right hip, chronic pronation and external rotation exert chronic passive tension-related forces to the anterior hip capsular ligaments, the hip internal rotator muscles (i.e., anterior fibers of Gluteus minimus and medius and tensor fascia latae), and the hip aDductors. This often can cause a tension-related tendinosis, particularly, at the Gluteus minimus and medius femoral trochanteric attachments, which can be confused with and is often mistreated steroidally as trochanteric bursitis, and the aDductor attachments along the pubic ramus.

Constant overuse activation of the external rotator muscles may eventually produce decompensatory fatigue with the advent of easily triggered muscle spasm, trigger points, and chronic active degenerative tendinosis at those tendinous attachment sites. The diagnosis of a chronic active tension-related “Piriformis Syndrome”—which is often thought to be totally isolated and “idiopathic” or is misdiagnosed as “bursitis” and/or mistreated with inappropriate steroid injection (i.e., for an inflammatory process or “tendonitis” that does not exist)—is common in RFL. The excessive vaulting nature of the long leg gait also can exert accentuated compressive force on the hip articular and labral structures, placing that hip at greater risk of wear-and-tear joint articular surface and labral damage.

Potential Prolotherapy Targets for RFL: Definitive treatment of patients with RFL consists, first, of OMT and whatever Prolotherapy is required of the underlying LSJD, CLS, and LFSL injuries. All patients who remain symptomatic of RFL deserve assessment of additional Prolotherapy of the following tension-and-impact-compression-related injuries:

- **Medial-plantar foot ligament attachments—e.g., plantar calcaneonavicular (spring), short and long plantar, 1st tarsometatarsal ligaments—and Peroneus brevis tendon attachments**
- **Plantar fascial attachment from the medial to mid-calcaneus**
- **Peroneus brevis tendon attachment at tuberosity of the 5th metatarsal bone**
- **Medial ankle ligament attachments—e.g., deltoid ligament**
- **Medial knee ligament attachments—e.g., medial collateral and medial coronary ligaments**

- **Right anterior cruciate ligament attachments**
- **Medial tendon attachments—e.g., Popliteus, Semimembranosis, and Pes anserinus muscles**
- **Treating the sacrum, medial knee structures, and whatever Pes planus exists by Prolotherapy and orthotic therapy helps to correct patellar lateral misalignment and reduce lateral plateau compression**
- **Anterior hip capsular ligament attachments**
- **Lateral internal rotator pelvic and greater trochanter tendon attachments—e.g., Gluteus minimus and medius muscles—and pubic ramus adductor tendon attachments**
- **Lateral hip external rotator pelvic and greater trochanter tendon attachments—e.g., Piriformis, Gemilli, and Obturator muscles.**

Severity Grading: Biotensegrity lesions characteristic of RFLL are generally graded as *Grade II of IV* in severity.

Compensatory left functionally long leg (LFLL), routinely found in RSIIJD, presents with the mirror-image opposites of potential Prolotherapy targets and equal grading severity requiring equal consideration of treating the mirror-image targets for Prolotherapy.

ACCENTUATED SCOLIOSIS IN SIJD

In the more usual presentation of the LSIIJD version of SIJD, the left ilium is anteriorly flexed and the right ilium is posteriorly extended. Consequently, the iliolumbar ligaments perform a tethering function, limiting L4-5 vertebral rotation—thus, limiting right lumbosacral side-bending.

However, if the left ilium rotates and extends posteriorly and right ilium rotates and flexes anteriorly, the lumbar levoscoliotic curvature can be accentuated. The latter, “reversed” ilial flexion presentation was a rare but significant finding—3 of the 44 (7%) LSIIJD patients—as observed in the Part III study. Such an ilial reversal can cause a paradoxical pulling on the L4 and L5 transverse processes by the iliolumbar ligaments that are anchored at the ilium, rotating those lumbar vertebrae even more anteriorly toward the left—and causing those vertebral bodies to side-bend to an even greater degree to the right in coupled Type I motion.

These reversed ilial rotations can dramatically increase the severity of the lumbar levoscoliosis and drastically complicate Prolotherapy and post-Prolotherapy rehabilitation in SIJD. Moreover, this event significantly increases the potential severity of nerve root involvement on the right, concave side due to the greater lumbar curvature and increased biotensegritous compression; see “A Perfect Storm,” below. The severely increased scoliosis consequent to such an ilial reversal calls for vigorous manual therapy, aggressive Prolotherapy, and disciplined rehabilitative therapy to all involved sacral, ilial, and vertebral structures. It requires a vastly different therapeutic strategy as to what structures should receive Prolotherapy, first, and what adjunct therapies need to be in play from the very beginning and thereafter. Otherwise, the patient is likely headed toward surgical intervention—and definitely deserves an Orthopedic consultation. Could accentuated scoliosis in SIJD be a cause of so-called “idiopathic” scoliosis?

Severity Grading: Biotensegrity lesions characteristic of the accentuated scoliosis in LSIIJD generated by right iliac flexion are generally graded as *Grade III of IV* in severity—and may progress to Grade IV with the advent of a “Perfect Storm.”

The reverse of all the above events described in accentuation of lumbar scoliosis can be seen in RSIIJD.

A “PERFECT STORM” IN SIJD

Occasionally, one will detect sensory (e.g., paresthesia, numbness) and motor (e.g., foot drop) symptoms and signs indicative of right-sided L5-S1 and/or L4-L5 nerve root compression in a patient with a left-sided SIJD having the aforementioned CLLS, LFSL, and RFLL. Those truly neurological signs and symptoms can include transient to blatant right leg radicular paresthesia and pain with muscle weakness with early to profound right foot drop (i.e., true sciatica). It usually occurs on the side of the concave lumbar arc where the compression forces are the greatest—in the case of LSIIJD, on the right, functionally long leg side. Bona fide sciatica can be easily confused with—or may be coexistent with—ligament referred pain (false sciatica) that can mimic true neurological sciatica—except for the motor symptoms. And, of course, there can be the atypical case of true nerve compression on the left, lumbar-concave side, but that is even more unusual because the convex arc of the right side-bent lumbar curve protects against that from happening.

The combined occurrence of chronic ligamentous pain of all the components of LSIJD plus the acute pain and motor deficit of sudden nerve root compression can result in a catastrophic clinical picture that fits that of a “Perfect Storm”—an example of two clinically severe Biotensegrity “storms” colliding—i.e., that of severe LSIJD on the left side of the convex lumbar arc and severe nerve root compression on the right side of the concave lumbar arc. Such a patient can be in extreme distress, totally disabled—literally bent over by back pain—and even requiring being carried into the clinic. There is an even higher risk of such a “Storm” occurring when the scoliosis is accentuated by the aforementioned “reversed” ileil flexion.

It is important to know that those emergency neurological symptoms and signs usually respond readily to manual therapy correction of the sacral displacement. Thus, leveling the sacral base can immediately reduce the left SIJD symptoms and signs, as well as reduce the right lumbar compressive forces on affected intervertebral discs, foramina, and the exiting nerve roots. Sixty seconds of applying very mild, low velocity, manual decompression of the sacral subluxation—thereby stabilizing the sacral base and, thus, reducing the right lumbar compression—usually can relieve all or most of the patient’s severe, acute discomfort. Then, instead of rushing into emergency back surgery, continued stabilization with a judiciously employed sacroiliac belt accompanied by aggressive Prolotherapy of the SIL and ILL over an average of three sessions followed by appropriate physical rehabilitation can save the patient’s day—and thwart unnecessary and potentially disabling surgery.

Of course, one should always obtain a surgical consultation. And, it is occasionally necessary for surgical treatment of degenerative disk disease with persistent and extremely severe lumbar nerve root impingement—but not as often as surgeons and the public tend to think. Most often, the patient’s final narrative summary will document sustained patient relief after OMT and Prolotherapy with no need for surgical intervention. If back surgery is clinically mandatory, achieve sacral stabilization by Prolotherapy before the surgery, if at all possible.

Severity Grading: Biotensegrity characteristic of severe LSIJD complicated by acute, severe nerve root compression are generally graded as *Grade IV of IV* in severity.

The mirror-image of all the above events described for a “Perfect Storm” in LSIJD can be expected in RSIJD.

SUMMARY

Biotensegrity incorporates neuromusculoskeletal tension-compression structural elements and forces that not only counter gravity, viz., the classical Fuller-Snelson model, but also generate additional, adaptive posturing to minimize neurological injury. Stable sacral alignment is a keystone to maintaining functional Biotensegrity. Resolving chronic sacral displacement is the key to resolving many lesions of Biotensegrity dysfunction.

Each patient with sacral dysfunction represents a unique Biotensegrity spectrum of balance and imbalance with infinite degrees of diagnostic possibilities. But, all three kinetic chains will be involved, presenting with their major defining manifestations to one degree or another. There can be variations of the theme with occasional exceptions to the general rules, particularly since many patients may be found caught in the midphase between a physiological restriction and a nonphysiological subluxation. But, recognizable patterns will emerge, offering hints as to where to look next. Such hints should guide decisions for staging treatment and joint stabilization based on analytical reasoning versus rote teaching. For example, if the lumbar spine is at risk of accentuated scoliosis in SIJD, it may be wise to treat the iliolumbar ligaments with Prolotherapy and stabilize the lower lumbar vertebrae before treating the sacroiliac ligaments to stabilize the sacrum. Additionally, SIJD should be further scrutinized as a cause of idiopathic scoliosis and Prolotherapy with body work as treatment in lieu of a back brace and the Herrington rod.

This series of four articles has presented a combination of Empirical, Deductive, Inductive, and Abductive clinical observations regarding back pain, sacral dysfunction, and Prolotherapy. Conclusions have been based on a Scientific Method approach to clinical practice—limited by nonrandomization. Many questions remain. For example, the Biotensegrity model described, here, needs to be further validated and characterized by other clinicians. Also, the differential effect of passive versus active tension on ligament and tendon needs to be further characterized. Biotensegrity patterns need to be further developed for various musculoskeletal regions other than the sacral kinetic chains herein described. Should preventive Prolotherapy be performed at nonpainful

attachment sites that are at high risk of being subclinically injured?

Given all the art and engineering forms available, there is no better model of Biotensegrity than the human form. Applying a functional Biotensegrity model clinically to sacroiliac sprain injury can reveal abundant targets for Prolotherapy from the plantar arch to the nuchal line, facilitating more efficacious diagnosis, treatment, and patient recovery—and prevention of further injury.

REFERENCES

1. Clark GB, Building a rationale for evidence-based prolotherapy in an orthopedic medicine practice. Part I. A short history of logical medical decision making. *Journal of Prolotherapy*. 2(Nov):512-519;2010.
2. Clark GB, Building a rationale for evidence-based prolotherapy in an orthopedic medicine practice. Part II. How to meld scientific methodology into the daily practice of prolotherapy. *Journal of Prolotherapy*. 3(Feb):582-587;2011.
3. Clark GB, Building a rationale for evidence-based prolotherapy in an orthopedic medicine practice. Part III: A case series report of chronic back pain associated with sacroiliac joint dysfunction treated by prolotherapy. A six-year prospective analysis. *Journal of Prolotherapy*. 3(May):632-639;2011.
4. "Tensegrity" Wikipedia. 26 March 2011: <http://en.wikipedia.org/wiki/Tensegrity>.
5. Levin S. The importance of soft tissues for structural support of the body. *Spine*. 9(May);1995.
6. "Sacrum" Online Etymology Dictionary. 26 March 2011: <http://www.etymonline.com/index.php?term=sacrum>.
7. Walker E. When I use a word. Pelvis. *Brit Med J*. Volume 325, Number 7358>BMJ325:264 doi:10.1136/bmj.3257538.264 (Published 3 August 2002).
8. "Sacrum" Wikipedia. 26 march 2011: <http://en.wikipedia.org/wiki/Sacrum>.
9. Bohannon RW. Number of pedometer-assessed steps taken per day by adults: a descriptive meta-analysis. *Physical Therapy*. December 2007, vol 87, no 12, 1642-1650.
10. Ravin T, Cantieri M, Pasquarello G. *Principles of Prolotherapy*. Denver, CO: American Academy of Musculoskeletal Medicine; 2008, p. 40-44.
11. Right-handedness. Wikipedia. 26 March 2011: <http://en.wikipedia.org/wiki/Right-handedness>.
12. Landis MC, Bracha HS, Brugger P. Opposite turning behavior in right-handers and non-right-handers suggests a link between handedness and cerebral dopamine asymmetries. *Behav Neurosc*. 2003 Dec;117(6):1448-52.
13. Heitz NA, Eisenman PA, Beck CL, Walker JA. Hormonal changes throughout the menstrual cycle and increased anterior cruciate ligament laxity in females. *J Athletic Training*. 1999 June;34(2):144-49.
14. Dragoo JL, Lee RS, Benhaim P, Finerman GAM, Hame SL. Relaxin receptors in the human female anterior cruciate ligament. *Am J Sports Med*. 2003 July;31(4):577-584.

ACKNOWLEDGEMENTS

The author is grateful to Fran Brown, BA; Matt Enos, CPI; Allen Parker, EdD; Michael Smith, MD; Joseph Swartz, MD, for their generous editorial support. Many thanks to Nicole Baird and Travis Mitchell for their valuable staff support. I want to especially thank Thomas Ravin, MD, for his explaining the basics of Biotensegrity to me—many ski seasons ago. This article is dedicated to the memory of Michael W. Seamans, DO, who taught me the intricacy of sacral examination and subtlety of its manipulation. ■

Are you looking for medical liability insurance that covers all the procedures of your medical practice?



Professional Liability Solutions LLC is an independent insurance broker specializing in customized solutions to your insurance needs. *Annual premiums have never been lower!*

CALL ED KUHN TODAY FOR A FREE CONSULTATION...

800-871-6871

email: edkuhn60@hotmail.com
www.medmalpractice-ins.com